



PATIENT

Zoey Westerhof

SPECIES

Canine

BREED

Dachshund

SEX

Female Spayed

AGE

12 years

WEIGHT

20.1lbs

INTERPRETED BY

Maggie Machen Lamy,
DVM, DACVIM
(Cardiology)

IMAGING PERFORMED BY

Kelly Vazquez, CVT

HOSPITAL NAME

Westwood Regional
Vet Hospital

REFERRING VET

Dr. Hartwick

INVOICE

24852

DATE

6/17/22

PRESENTING CLINICAL SIGNS

History: Recheck echo. Grade 4/6 heart murmur. Asymptomatic. Assess prior to dental.
-Current medications: Pimobendan 2.5mgs.
-Pertinent previous echo findings (9/2021 EL): CVD B2 with MR, TR and AI. LA/AO: 2.0.

ECHOCARDIOGRAM FINDINGS

2D, m-mode, color flow and doppler imaging is available. The mitral valve is diffusely thickened with mild prolapse into the left atrial lumen. There is severe eccentric mitral regurgitation present. The MR velocity is normal. There is severe left atrial enlargement. There is mild left ventricular dilation. Left ventricular systolic function is hyperdynamic. Mild right atrial and ventricular dilation (subjective). Mild thickening of the tricuspid valve with mild TR. There is normal systolic flow velocity across the aortic valve. The aortic valve appears trileaflet with normal mobility. Moderate aortic insufficiency. The main pulmonary artery is normal in diameter. The pulmonic valve is normal in appearance. No pericardial/pleural effusion or cardiac masses are seen.

CARDIAC CHART

CANINE CARDIAC PARAMETERS	MR VMAX (m/s)	TR VMAX (m/s)	LA/AO (Boon method)	LA/AO (Heart Base; Swe)	FS (%)	EF (%)	EPSS (cm)
NORMAL PARAMETER	4.5-5.5	<2.7	1.3	<1.6	28-40	40-100	<0.6
PATIENT	5.8	NM	1.7	2.4	35	65	NM
CANINE CARDIAC PARAMETERS	HR (BPM)	AV VMAX (m/s)	PV MAX (m/s)	BODY WEIGHT (kg)	LA 2D short axis Base view (cm)	LVIDd Avg; 2D and m-mode short axis (cm)	LVIDs Avg; 2D and m-mode short axis (cm)
NORMAL PARAMETER	50-100	0.7-1.7	0.7-1.6	BELOW	BELOW	BELOW	BELOW
PATIENT	111	1.5	0.93	9.1	2.8	4.0	2.0
*Normal chamber parameters expressed as a mean value (SD)							
BODY WEIGHT DEPENDENT PARAMETERS							
<i>*Note: All measurements based upon multi-modal images and methods. An average value is reported.</i>							
Adapted from June Boon, Veterinary Echocardiography, 1998				3	1.27 (5.3)	2.46 (2.46)	1.36 (5.5)
Rishniw M and Hollis NE, J Vet Intern Med 2000; 14:429-435				5	1.40 (4.5)	2.74 (5.2)	1.60 (4.7)
Hansson et al, Vet Rad and Ultrasound 2002				10	1.50 (3.8)	3.27 (3.5)	2.06 (3.1)
Bonagura et al. Echocardiography: principles of interpretation, Vet Clin North Am 15:1177, 1995				15	1.83 (2.0)	3.71 (2.4)	2.43 (2.1)
				20	2.02 (1.9)	4.14 (2.2)	2.80 (2.0)
				25	2.18 (2.4)	4.48 (2.9)	3.10 (2.5)
				30	2.33 (3.3)	4.83 (3.9)	3.39 (3.4)
				35	2.48 (4.3)	5.17 (5.0)	3.69 (4.5)
				40	2.62 (5.2)	5.48 (6.1)	3.96 (5.4)
				50	2.88 (7.1)	6.07 (8.3)	4.46 (7.4)

INTERPRETATION OF THE FINDINGS & FURTHER RECOMMENDATIONS

Chronic degenerative valve disease persists with severe mitral and mild tricuspid regurgitation. Compared to the prior study, there is evidence of progression in left heart dimensions. The aortic leak is significant, and a baseline blood pressure is strongly recommended. No additional issues are documented.

With this degree of left heart changes, the risk for spontaneous congestive heart failure is elevated and cardiac supportive medications are indicated as below. A weak diuretic (spironolactone) is included given high risk for decompensation in the future even with no



PATIENT

Zoey Westerhof

reported symptoms. Assessment of progression in the future will help predict long term outcome, however prognosis is guarded at this stage (late B2). Unfortunately, the patient will always be at risk for recurrent CHF, development of arrhythmias/LA tear, syncope and/or sudden death in the future.

SPECIES

Canine

Close monitoring for development of associated clinical signs (development of a cough, labored breathing, exercise intolerance or worsening collapse episodes) is recommended. **Monitoring of sleeping breathing rates is recommended as the best way to screen for CHF at home.**

BREED

Dachshund

Elective anesthesia is not advised, as there is high risk for complication. If necessary, cardiac protective drug choices (opioid/benzodiazepine premedication, propofol or alfaxalone induction, iso or sevoflurane gas) are recommended. Pre-oxygenate for 5-10 minutes prior to induction and recover in O2 cage. Monitor for arrhythmias, hypotension, and hypoxia both intra and post-operatively and intervene as necessary. Moderate IV fluid restriction is recommended to avoid fluid overload. Avoid heart rate stimulating drugs such as atropine unless clinically indicated.

AGE

12 years

Omega fatty acid supplementation and mild salt restriction may also be of some long-term benefit.

WEIGHT

20.1lbs

PLAN

A screening BP is recommended with monitoring every 6 months. Continue Pimobendan 0.3mg/kg PO q12h. Institute ACE-I (benazepril or enalapril) 0.5mg/kg PO q12h. Institute spironolactone 1-2mg/kg PO q12h.

INTERPRETED BY

Maggie Machen Lamy,
DVM, DACVIM
(Cardiology)

Monitor renal values in 1-2 weeks, then every 3-4 months lifelong to ensure tolerance of medications.

A recheck echocardiogram is recommended in 4-6 months to screen for progression, sooner if clinical signs arise.

IMAGING PERFORMED BY

Kelly Vazquez, CVT

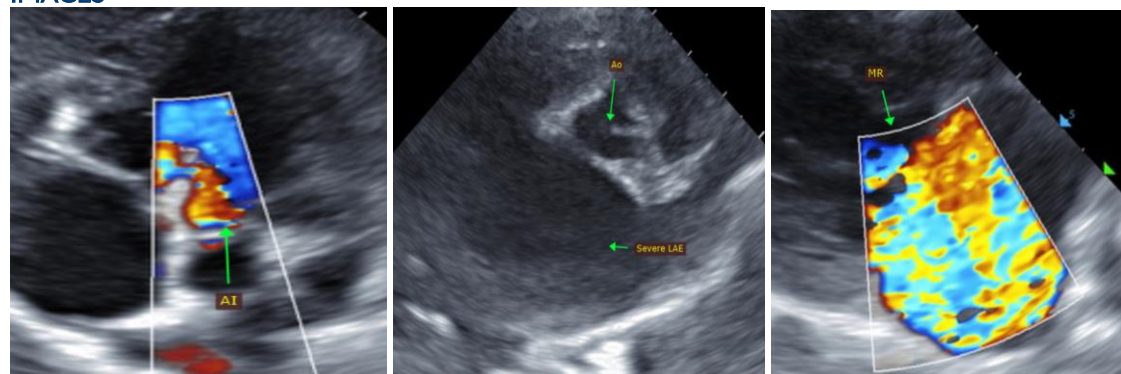
HOSPITAL NAME

Westwood Regional
Vet Hospital

REFERRING VET

Dr. Hartwick

IMAGES



INVOICE

24852

DATE

6/17/22



PATIENT

Zoey Westerhof

The information and recommendations provided are based on the images presented by the referring veterinarian. No evaluation can be communicated regarding pathology that was not visible in the image/video clips provided.

SPECIES

Canine

Thank you for this referral. This report was generated using transcription software, and minor dictation errors may be present. If the clinical or image interpretation does not parallel your findings or if I can be of any further assistance, please contact me.

BREED

Dachshund

Maggie Machen Lamy, DVM
Diplomate of the American College of Veterinary Internal Medicine (Cardiology)
info@sonopath.com

SEX

Female Spayed

AGE

12 years

WEIGHT

20.1lbs

INTERPRETED BY

Maggie Machen Lamy,
DVM, DACVIM
(Cardiology)

**IMAGING
PERFORMED BY**

Kelly Vazquez, CVT

HOSPITAL NAME

Westwood Regional
Vet Hospital

REFERRING VET

Dr. Hartwick

INVOICE

24852

DATE

6/17/22